



JOIS

CASE SERIES

Oral soft tissue wound healing following the application of an oxygen-releasing gel: a case series

SÉRIE DE CASOS

Cicatrização de feridas em tecidos moles orais após a aplicação de um gel liberador de oxigênio: uma série de casos

Yao Zu Sia¹

Yet Ching Goh²

Renukanth Raman³

Chuey Chuan Tan⁴

Wei Cheong Ngeow⁵

Chia Wei Cheah⁶

Autor de correspondência:

chiawei@um.edu.my

¹ BDS, Klinik Pergigian Dr Gabriel Sia, 1-1 Dagang Cahaya, Jalan Dagang 5, Taman Dagang, 68000, Ampang, Selangor, Malaysia.

² Yet Ching Goh, BDS, MClintDent, Department of Oral & Maxillofacial Clinical Sciences, Faculty of Dentistry, Universiti Malaya, 50603 Kuala Lumpur, Malaysia

³ BDS, MClintDent, Ministry of Health Malaysia, Oral Health Division, Ministry of Health Malaysia, 62590 Putrajaya, Malaysia

⁴ BDS, MClintDent, Department of Oral & Maxillofacial Clinical Sciences, Faculty of Dentistry, Universiti Malaya, 50603 Kuala Lumpur, Malaysia

⁵ BDS, MSc, PhD, Department of Oral & Maxillofacial Clinical Sciences, Faculty of Dentistry, Universiti Malaya, 50603 Kuala Lumpur, Malaysia

⁶ BDS, MClintDent, PhD, Department of Restorative Dentistry, Faculty of Dentistry, Universiti Malaya, 50603 Kuala Lumpur, Malaysia

Abstract

Keywords: Wound Healing; Oral Mucosa; Hydrogels; Oxygen; Bacterial Load; Soft Tissue Injuries.

Oral soft tissue healing represents a clinical challenge due to continuous exposure to saliva, mechanical stress, and a complex microbial environment that may impair tissue repair. Novel therapeutic approaches aimed at optimizing local oxygen availability have emerged as promising adjuncts in wound management. This manuscript aims to evaluate the clinical outcomes of oral soft tissue wound healing following the topical application of an oxygen-releasing gel in different clinical scenarios involving oral mucosal injury. Patients presenting with oral soft tissue wounds of distinct etiologies were treated with a topical oxygen-releasing gel as an adjunctive therapy. The gel releases active oxygen upon contact with saliva, promoting angiogenesis and creating a favorable microenvironment for tissue regeneration while limiting anaerobic bacterial proliferation. Clinical healing outcomes were assessed based on tissue repair progression and postoperative recovery. Favorable healing responses were observed across all cases, with accelerated epithelialization, reduced inflammatory signs, and uneventful healing patterns. Based on the findings of this case series, we can conclude that the topical application of an oxygen-releasing gel showed promising clinical outcomes as an adjunctive approach for oral soft tissue wound management. Oxygen-delivering hydrogels may represent a biologically compatible and effective strategy to enhance tissue repair in oral clinical practice.

Resumo

Palavras-chave: Cicatrização de Feridas; Mucosa Oral; Hidrogéis; Oxigênio; Carga Bacteriana; Lesões de Tecidos Moles.

A cicatrização de tecidos moles orais representa um desafio clínico devido à exposição contínua à saliva, ao estresse mecânico e a um ambiente microbiano complexo que pode prejudicar o reparo tecidual. Novas abordagens terapêuticas voltadas para a otimização da disponibilidade local de oxigênio têm surgido como adjuvantes promissores no manejo de feridas. Este manuscrito tem como objetivo avaliar os desfechos clínicos da cicatrização de feridas em tecidos moles orais após a aplicação tópica de um gel liberador de oxigênio em diferentes cenários clínicos envolvendo lesões da mucosa oral. Pacientes que apresentavam feridas em tecidos moles orais de diferentes etiologias foram tratados com um gel tópico liberador de oxigênio como terapia adjuvante. O gel libera oxigênio ativo ao entrar em contato com a saliva, promovendo angiogênese e criando um microambiente favorável à regeneração tecidual, além de limitar a proliferação de bactérias anaeróbias. Os resultados clínicos da cicatrização foram avaliados com base na progressão do reparo tecidual e na recuperação pós-operatória. Respostas favoráveis de cicatrização foram observadas em todos os casos, com epitelização acelerada, redução dos sinais inflamatórios e padrões de cicatrização sem intercorrências. Com base nos achados desta série de casos, podemos concluir que a aplicação tópica de um gel liberador de oxigênio apresentou resultados clínicos promissores como abordagem adjuvante no manejo de feridas em tecidos moles orais. Hidrogéis liberadores de oxigênio podem representar uma estratégia biologicamente compatível e eficaz para potencializar o reparo tecidual na prática clínica odontológica.

Introduction

The oral mucosa serves as a critical protective barrier against mechanical stress, physical trauma, and microbial invasion. Following injury, oral tissues undergo a complex and dynamic sequence of biological events aimed at restoring structural integrity and functional homeostasis. Unlike cutaneous tissues, the oral mucosa exists within a constantly moist and warm environment exposed to saliva and a diverse microbial ecosystem, factors that may significantly influence wound healing outcomes^{1,2}. Both local and systemic conditions play an essential role in determining the quality and predictability of tissue repair. Impaired healing may compromise the architectural integrity of oral tissues, potentially resulting in functional limitations and morphological alterations³.

In clinical practice, haemostasis represents the initial and fundamental phase of wound healing, providing a stable environment for clot formation and subsequent tissue regeneration. Conventional approaches to postoperative bleeding control commonly involve the use of gauze or cotton compression to promote clot stabilization⁴. However, advances in biomaterial science have led to the development of modern wound dressings designed not only to achieve haemostasis but also to enhance tissue protection, improve patient comfort, prolong adhesion, and support biologically favorable healing conditions^{4,5}.

Currently, several intraoral wound management materials derived from synthetic and biological sources are available. Synthetic agents include hyaluronic acid formulations, chlorhexidine gels, cyanoacrylates, lipophilic polymer complexes, and oxygen-releasing topical gels, whereas biological materials are commonly obtained from plant or animal origins (Table 1).

Among these therapeutic approaches, hydrogels have attracted considerable attention due to their high-water content and structural similarity to the natural extracellular matrix. These hydrophilic polymer networks are capable of absorbing and retaining large amounts of water while maintaining structural stability, thereby recreating a hydrated microenvironment conducive to cellular migration, proliferation, and tissue regeneration^{6,7} additionally, hydrogels function as effective drug-delivery systems, enabling the controlled release of bioactive compounds that may enhance the wound healing process³.

The application of functional hydrogels is particularly advantageous in the oral cavity, where constant saliva flow and functional movements often limit the retention of conventional topical agents. Oxygen-releasing hydrogels represent an emerging therapeutic strategy by improving local oxygen availability, supporting angiogenesis and cellular metabolism, while contributing to the control of anaerobic microbial proliferation⁵.

Therefore, the present manuscript reports a case series describing the clinical application of a topical oxygen-releasing hydrogel (blue®m) in the management of oral and maxillofacial soft tissue wounds, aiming to illustrate its potential to enhance tissue healing while maintaining oral microbiome balance.

Table 1. Different gel formulations from various sources for intra-oral wound applications

Product	Properties/ mechanism	Type of wound	Remarks
Topical oxygen gel	Production of oxygen	Medication-related osteonecrosis of the jaw ⁵	Recovery of the long standing osteonecrosis lesion
Hyaluronic acid (film or gel)	Linear polymer of glucuronic acid and N-acetylglucosamine disaccharide	Rat's tongue ⁶	
		Extraction socket of patients with Uncontrolled Type II diabetes ⁷	Better wound closure rate and wound healing scale
Chlorhexidine	0.2% concentration	Extraction socket ⁸	Better wound closure and higher Landry wound healing index
Periacryl	n-butyl cyanoacrylate (fast setting) and 2-octyl cyanoacrylate (flexible)	Coronally advanced flap ⁹	Better wound stability
		Palatal wound ¹⁰	Faster epithelization
Adhesive - oral aid	An outer layer composed of lipophilic polymer complex; an inner layer: hydrophilic polymer complex; mucoadhesive layer; reacts with	Palatal graft donor site ¹¹	Reduce post-operative bleeding in the first 24 hours, reduce operative time

Case Series

Case 1

A 34-year-old Malay male patient was referred to the Periodontal Clinic with a chief complaint of gingival recession affecting the mandibular anterior teeth, primarily associated with aesthetic concerns and dentin hypersensitivity to dietary stimuli. The patient reported that the gingival recession became noticeable following orthodontic treatment performed to correct dental malalignment. Clinical examination revealed multiple facial gingival recession defects in the lower anterior region. Recession depth of approximately 3 mm was observed on teeth 33, 32, and 31, classified as RT2 defects, while tooth 41 presented 1.5 mm of recession (RT1). Teeth 42 and 43 demonstrated approximately 1 mm of recession, also classified as RT1 (Figure 1a). Root coverage surgery was performed using a tunnelling technique combined with a donor human dermal matrix graft to promote soft tissue augmentation and improve

gingival thickness. Following flap stabilization and suturing, a topical oxygen-releasing gel (Blue@m) was applied immediately over the surgical site (Figure 1b). The patient was instructed to continue topical application twice daily for five days during the postoperative healing period. At the 5-day postoperative evaluation, sutures were removed, revealing favorable early wound healing characterized by adequate tissue adaptation, absence of inflammatory signs, and satisfactory soft tissue integration (Figure 1c). The surgical outcome resulted in improvement of gingival coverage, with resolution of hypersensitivity symptoms and satisfactory aesthetic enhancement.

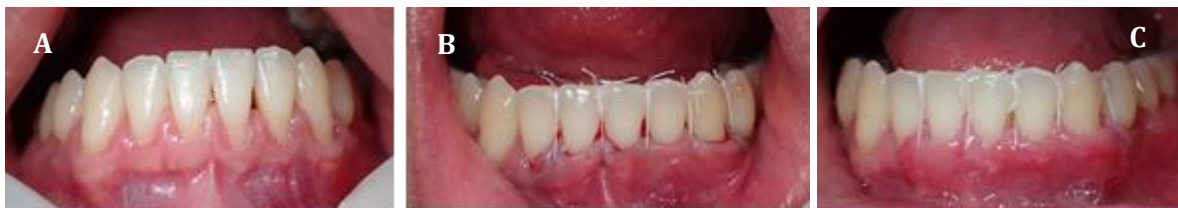

Figure 1 - A 34-year-old male with multiple recession on lower anterior teeth (a). There is a combination of RT1 and RT2 recession defects on teeth 33 to 43. Recession coverage was done using donor dermal graft and the tunnelling technique (b). Blue@m gel was applied immediately post-op and the patient was instructed to apply the gel twice daily for 5 days. Sutures were removed at day 5 with very satisfactory healing (c).

Case 2

A 56-year-old female patient previously diagnosed with Generalized Periodontitis Stage IV, Grade B underwent successful Initial Cause-Related Therapy. Following periodontal stabilization, a localized residual deep periodontal pocket persisted at the mesial aspect of tooth 23, associated with an intrabony defect (Figure 2a). Periodontal regenerative surgery was indicated and performed using a Modified Minimally Invasive Surgical Technique (M-MIST) to preserve soft tissue integrity and enhance regenerative outcomes. The intrabony defect was treated with an alloplastic graft material (EthOss® biphasic synthetic graft), selected due to its complete resorption profile and handling characteristics. Primary wound closure was achieved using a single modified Laurell suture, followed by immediate application of a topical oxygen-releasing gel

(Blue@m) over the surgical site (Figure 2b). The patient was instructed to apply the gel twice daily for five days during the early postoperative healing phase. At the 5-day postoperative visit, sutures were removed, demonstrating complete approximation of the surgical wound margins with favorable early healing and absence of inflammatory signs (Figure 2c). Clinical reassessment performed three months postoperatively revealed complete resolution of the periodontal pocket without additional gingival recession compared with baseline conditions. Radiographic evaluation demonstrated evident hard tissue fill consistent with regeneration of the intrabony defect.

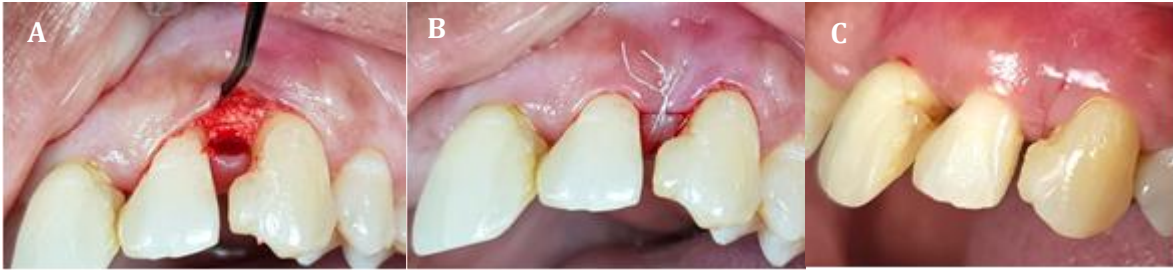

Figure 2 - In this second case, a 56-year-old female has periodontal intrabony defect on mesial of tooth 23 (a). Periodontal regenerative surgery was done with an alloplastic graft. Primary closure was achieved with a single modified Laurel suture and Blue@m gel applied immediately post-op (b). Patient was subsequently instructed to apply the gel twice daily for 5 days. Sutures were removed at day-5 and the surgical wound margins had completely approximated and healed (c).

Case 3

A 45-year-old male patient presented with an edentulous area at tooth site 46 indicated for dental implant placement (Figure 3a). Implant surgery was performed following standard surgical protocols. After implant insertion, primary wound closure was achieved using nylon sutures to ensure adequate soft tissue adaptation. Immediately after suturing, a topical oxygen-releasing gel (Blue@m) was applied to the surgical site (Figure 3b). The

patient was instructed to apply the gel topically during the postoperative healing period according to the recommended protocol. At the 7-day postoperative evaluation, complete wound closure was observed with satisfactory soft tissue healing. Sutures were subsequently removed, demonstrating favorable tissue response without signs of inflammation or postoperative complications (Figure 3c).

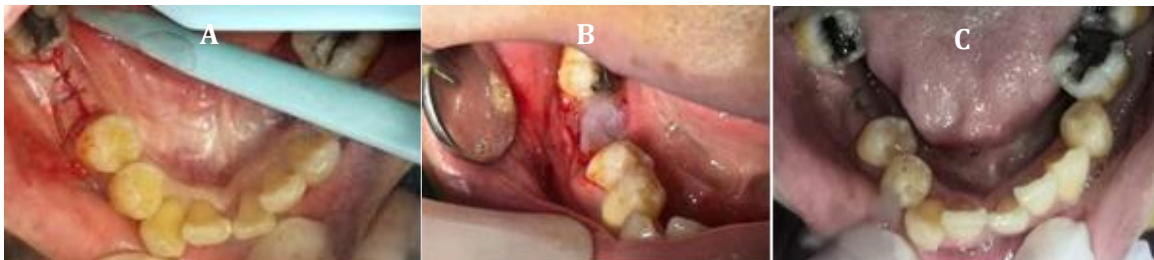


Figure 3 - This third case is a 45-year-old male with edentulous tooth 46 for implant placement (a). After implant surgery, the wound was closed primarily with nylon suture and the application of Blue@m gel (b). On post operative day 7, wound showed full closure and sutures removal was performed (c).

Case 4

A 43-year-old female patient presented with an edentulous area at tooth site 37 indicated for dental implant placement. Implant surgery was performed following conventional surgical protocols, and primary wound closure was achieved after implant installation. A topical oxygen-releasing gel (Blue@m) was applied directly over the sutured surgical site immediately after wound closure (Figure 4a). Approximately 10

minutes following application, a visible oxygen-releasing reaction was observed at the surgical area, indicating active oxygen delivery at the wound interface (Figure 4b). At the first postoperative day evaluation, the surgical site demonstrated favorable early healing characteristics, with adequate tissue adaptation and absence of inflammatory signs. At the first postoperative day evaluation, sutures were removed, and the surgical site demonstrated favorable early healing with satisfactory tissue adaptation and absence of inflammatory signs or postoperative complications (Figure 4c).

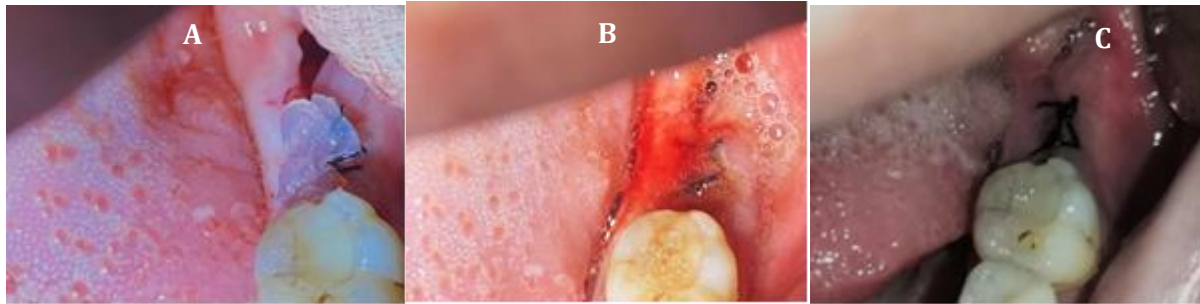


Figure 4 - Fourth case is a 43-year-old female with missing tooth 37 for implant placement. Application of Blue@m gel on the primary closure wound (a). The wound showed oxygen releasing effect after 10 minutes of Blue@m gel (b). On post operative day one, sutures removal was performed and wound appear good (c).

Case 5

A 26-year-old female patient presented with an edentulous area at tooth site 36 indicated for dental implant placement (Figure 5a). Implant surgery was performed according to conventional clinical protocols, followed by primary wound closure to ensure adequate soft tissue adaptation. After suturing, a topical oxygen-releasing gel (Blue@m) was applied over the surgical site and maintained in contact with the wound for

approximately 10 minutes (Figure 5b). A visible oxygen-releasing reaction was observed, indicating active oxygen delivery at the wound surface. At the first postoperative day evaluation, the surgical site demonstrated satisfactory early healing, with proper tissue approximation and absence of clinical signs of inflammation or complications. Sutures were removed, and the wound exhibited favorable clinical appearance and stability (Figure 5c).

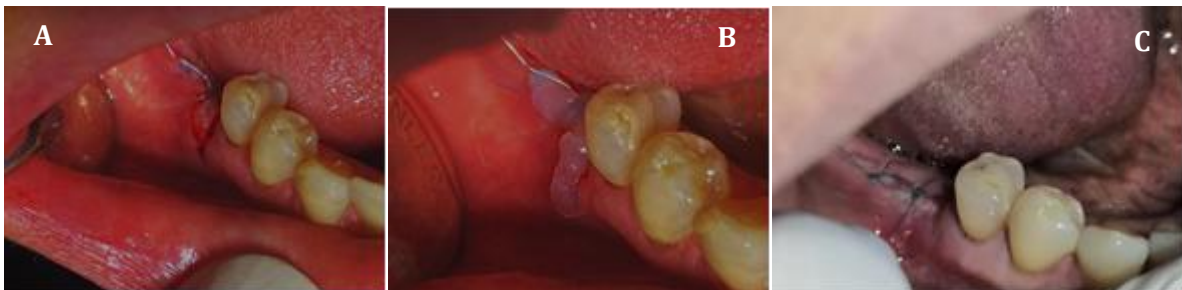

Figure 5 - This fifth case involves a 26-year-old female with missing tooth 36 for implant placement (a). Blue@m gel was placed on the primarily closed wound. The wound showed oxygen releasing effect after 10 minutes of Blue@m gel (b). On post operative day one, sutures removal performed and wound appeared good (c).

Case 6

A 27-year-old female patient, a breast cancer survivor with a previous history of chemotherapy, presented with hypodontia characterized by congenitally missing teeth 24, 25, and 35. Implant rehabilitation was planned, and the patient opted for implant placement. Implant surgery was performed at tooth site 35 following conventional surgical protocols. After implant placement, primary wound closure was achieved, and a topical oxygen-releasing gel (Blue@m) was applied over the sutured surgical site and maintained in contact with the wound for approximately 10 minutes to

support early healing (Figure 6a). At the first postoperative day evaluation, the surgical wound demonstrated satisfactory tissue adaptation and favorable early healing characteristics (Figure 6b). During the same surgical session, autogenous bone grafting was performed for future implant rehabilitation at sites 24 and 25. Bone was harvested from the torus palatinus using a rotary bone harvester following a T-shaped incision, yielding approximately 0.5 cc of autogenous bone. The palatal donor site was treated with topical application of Blue@m gel (Figure 6c) and protected with a BloodSTOP® IX dressing to assist hemostasis and soft tissue stabilization (Figure

6d). At postoperative day one, the palatal donor site exhibited satisfactory granulation tissue formation, while the implant site at tooth 35 showed adequate wound stability and absence of inflammatory signs.

Sutures were removed, demonstrating uneventful healing at both surgical areas (Figure 6e).

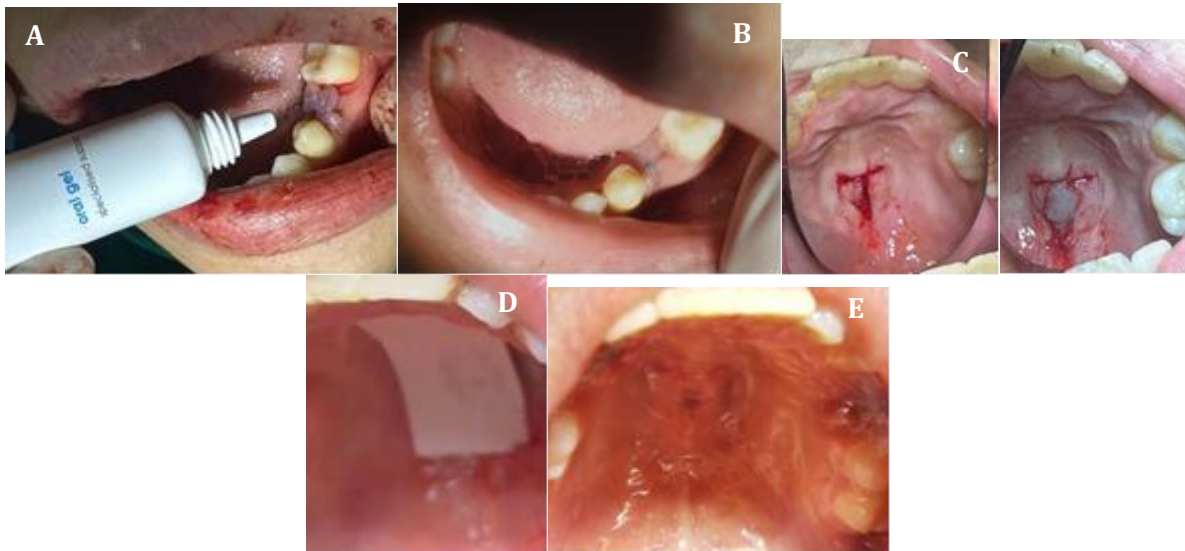


Figure 6 - This sixth case is a 27-year-old female breast cancer survivor with a history of chemotherapy. She presented with missing tooth 35 for implant placement (a,b). Implant surgery was performed with autograft harvested from torus palatinus. Application of Blue@m gel and Bloodstop IX was done over the palatal donor site (c,d). Blue@m gel also applied on the surgical site of 35. On postoperative day one, palatal wound was well granulated and the wound over tooth 35 showed good healing (e).

Discussion

Oxygen-delivering hydrogels have recently emerged as a promising adjunctive approach for wound management in oral and maxillofacial surgery. The oral cavity represents a challenging healing environment due to continuous microbial exposure, saliva contamination, and mechanical stress, factors known to influence wound stability and tissue repair outcomes^{1,2}. Enhancement of local oxygen availability has therefore been proposed as a biologically driven strategy to improve healing conditions in oral tissues^{5,8}.

The present case series demonstrated favorable clinical healing outcomes following adjunctive application of a topical oxygen-releasing hydrogel across different surgical indications, including mucogingival surgery, periodontal regeneration, implant placement, and procedures involving autogenous graft harvesting. Early wound stability and satisfactory tissue adaptation were consistently observed in all presented cases, allowing early suture removal without clinical signs of inflammation or wound dehiscence. Similar clinical benefits associated with topical oxygen therapy have been previously described in periodontal and implant-related surgical

procedures¹¹.

The positive healing responses observed may be explained by the essential role of oxygen in the physiological stages of wound healing. Adequate oxygen tension is required for oxidative phosphorylation and ATP production, which directly support fibroblast proliferation, epithelial migration, and tissue repair.⁸ Oxygen also plays a critical role in collagen synthesis through hydroxylation of proline and lysine residues, a process necessary for stabilization of the collagen triple helix and extracellular matrix formation⁸.

Additionally, sustained oxygen delivery has been shown to stimulate angiogenesis via upregulation of vascular endothelial growth factor (VEGF), promoting neovascularization and improving nutrient diffusion within regenerating tissues⁹. Improved oxygenation may accelerate transition from the inflammatory phase toward proliferative and remodeling stages of healing, contributing to faster clinical recovery.

Beyond its regenerative effects, oxygen availability influences microbial homeostasis. Increased oxygen tension inhibits the proliferation of anaerobic periodontal pathogens such as *Porphyromonas gingivalis* and *Tannerella forsythia*, microorganisms strongly associated with periodontal and peri-implant disease progression¹⁰. Furthermore, oxygen enhances



neutrophil and macrophage oxidative killing mechanisms, improving host immune response during early wound healing.

The oxygen-releasing hydrogel used in this case series contains sodium perborate, glucose oxidase, xylitol, and lactoferrin. Upon contact with tissue fluids, these components generate controlled low concentrations of hydrogen peroxide, enabling gradual oxygen release while maintaining biocompatibility. Previous investigations have demonstrated that lactoferrin contributes to angiogenesis modulation and collagen fiber formation while exerting antimicrobial activity, supporting favorable healing conditions⁸.

Recent clinical observations reported by Leventis et al.(2024)¹¹ described successful use of topical oxygen gel therapy in periodontal defects, peri-implant diseases, guided bone regeneration complications, and surgical wound management following cyst removal¹¹. Likewise, active oxygen therapy has been reported in the treatment of medication-related osteonecrosis of the jaw (MRONJ), achieving complete epithelialization after failure of conventional treatment modalities⁵. These findings support the growing evidence that oxygen-based topical therapies and controlled oxygen-delivery biomaterials may enhance healing outcomes in complex oral surgical scenarios¹¹⁻¹⁴. In addition, hydrogen peroxide-based adjunctive antimicrobial approaches and oxygen-carrier hydrogels have also demonstrated beneficial effects in periodontal therapy and tissue engineering^{12,13}.

Despite the encouraging clinical observations, the inherent limitations of a case series design, including lack of control groups and quantitative outcome measurements, must be acknowledged. Future randomized controlled clinical trials are necessary to validate the clinical effectiveness of oxygen-releasing hydrogels and to establish standardized protocols for their application in oral and periodontal surgery.

Conclusion

Based on the clinical observations presented in this case series, the adjunctive use of a topical oxygen-releasing hydrogel demonstrated favorable outcomes in oral soft tissue wound management across different surgical indications, including mucogingival surgery, periodontal regeneration, implant placement, and procedures involving autogenous graft harvesting. Consistent early wound stability, satisfactory tissue approximation, and uneventful postoperative healing were observed in all cases, including in a medically

compromised patient. The sustained release of oxygen may contribute to enhanced angiogenesis, collagen synthesis, microbial control, and improved local tissue metabolism, thereby supporting physiological wound healing processes within the challenging oral environment.

References

1. Ngeow WC, Tan CC, Goh YC, Deliberador TM, Cheah CW. A Narrative Review on Means to Promote Oxygenation and Angiogenesis in Oral Wound Healing. *Bioengineering (Basel)*. 2022;9(11):636.
2. Hao M, Wang D, Duan M, et al. Functional drug-delivery hydrogels for oral and maxillofacial wound healing. *Front Bioeng Biotechnol*. 2023; 11:1241660.
3. Zhou X, Cai Y, Zhao J. The hemostatic and comforting effects of oral adhesive bandages in tooth extraction. *Clin Oral Investig*. 2024; 28:244.
4. Varaprasad K, Raghavendra GM, Jayaramudu T, et al. A mini review on hydrogels classification and recent developments. *Mater Sci Eng C*. 2017; 79:958–971.
5. Deliberador TM, Stutz C, Sartori E, et al. Treatment of MRONJ with topical active oxygen gel. *Clin Cosmet Investig Dent*. 2024; 16:249–254.
6. Lee JH, Lee KE, Nam OH, et al. Orodispersible hyaluronic acid film delivery for oral wound healing. *J Dent Sci*. 2022;17(4):1595–1603.
7. Thang NH, Chien TB, Cuong DX. Polymer-Based Hydrogels Applied in Drug Delivery. *Gels*. 2023;9(7):523.
8. Shoulders MD, Raines RT. Collagen structure and stability. *Annu Rev Biochem*. 2009; 78:929–958.
9. Guan Y, Niu H, Liu Z, et al. Sustained oxygenation accelerates wound healing. *Sci Adv*. 2021;7: eabj0153.
10. Müller-Heupt LK, Eckelt A, et al. Local oxygen therapy as antimicrobial option for periodontitis. *Antibiotics*. 2023; 12:990.

11. Leventis M, Deliberador T, Alshehri F, Alghamdi H. Topical oxygen therapy in implantology and periodontology. *Saudi Dent J.* 2024;36(6):841-854.
12. Kanno T, Nakamura K, et al. Hydrogen peroxide adjunctive antimicrobial therapy. *Sci Rep.* 2017; 7:12247.
13. Özçelik H, Batool F, et al. Hyaluronic acid hydrogel containing extracellular oxygen carrier. *Int J Pharm.* 2021; 605:120810.
14. Müller-Heupt LK, Wiesmann-Imilowski N, et al. Oxygen-releasing hyaluronic acid dispersion for periodontal tissue engineering. *Int J Mol Sci.* 2023; 24:5936.

Como citar este artigo: Sia YZ, Goh YC, Raman R, Tan CC, Ngeow WC, Cheah CW. Oral soft tissue wound healing following the application of an oxygen-releasing gel: a case series *J Orofac Innov Sci.* 2026;3(1):1-9.